

Scalp reconstruction - Post-electric Burns

Ankita Anil Naik, Mahantesh Math, J. V. Morab

Department of Surgery, S. N. Medical College, Bagalkot, Karnataka, India

Abstract

Introduction: The electric burn injuries to scalp can be classified as; those with only pure soft tissue injuries and scalp burns involving the calvarium. Calvarial burns are extremely rare and are a challenge for both the plastic surgeon and the neurosurgeon.

Case report: We encountered an unusual case of high-voltage electrical burn of the head causing charring of scalp, bone and dura with herniation of infected brain matter with neurological deficit. A 50 year old male patient came to the casualty, in a disoriented state, with the alleged history of accidental electric burn injuries at multiple sites, including the scalp and the limbs. The scalp injury showed charring of the scalp and the skull with a defect over the calvaria with exposed dura mater. The patient underwent multiple surgical debridements, followed by serial dressings. The scalp defect was covered by a flap based on the posterior branch of left superficial temporal artery and a left forehead flap. A two-staged flap procedure was done; the outcome being survival of the patient and the survival of the flap.

Conclusion: Full thickness scalp defect with exposed dura following electric burn injury can be covered with versatile scalp flaps with satisfactory functional and aesthetic results.

Key words: reconstruction; electrical burns; scalp defect; scalp reconstruction.

Introduction

The burn injuries to hair-bearing scalp can be classified into two groups; those which are pure soft tissue injuries and scalp burns which involve the calvarium.^[1] Calvarial burns are extremely rare and pose a difficult challenge for both the plastic surgeon and the neurosurgeon.^[2] If the initial patient assessment indicates a full-thickness calvarial injury, that is, exposed dura; coverage of the defect with a vascularized flap should be the primary operative procedure. We encountered an unusual case of high voltage electrical burn of the head causing charring of scalp, bone and dura with herniation of infected brain matter with neurological deficit.

Case Report

A 50 year old male patient came to the casualty with the alleged history of accidental electric burn injuries to multiple sites, including the scalp, right forearm, right thigh and foot and left leg.

On examination, patient was drowsy and disoriented to time, place and person. The scalp injury showed charring of the scalp and the skull with defect of

6*5cms over the vertex and right parieto-temporal region with exposed dura mater (Fig. 1).

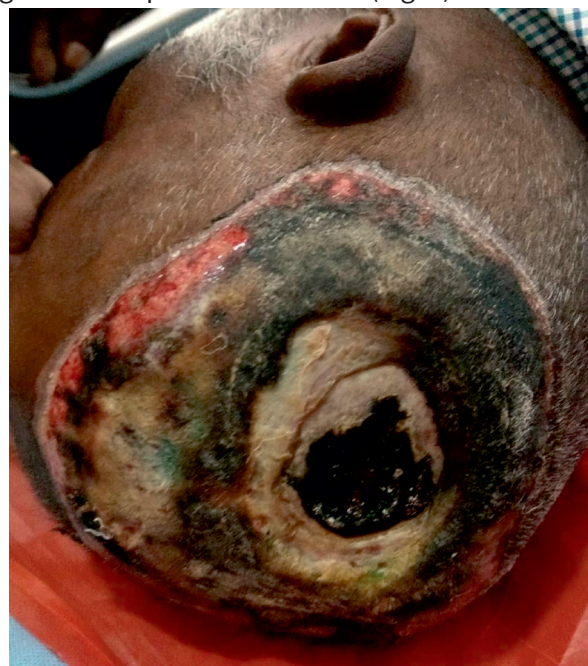

Figure 1. Charring of the scalp and the skull in right parieto-temporal region with exposed dura mater

Address for Correspondence:

Dr. Ankita Naik

Department of Surgery, S. N. Medical College, Bagalkot, Karnataka, India

E-mail: naikankitaaan@gmail.com

The general condition of the patient was poor and he was positive for HbsAg with deranged Liver function tests.

On admission, Computed Tomography of Brain (plain), showed focal irregular areas of full thickness bony erosions with associated overlying soft tissue defect involving posterior aspect of right parietal region (Fig 2). There were multiple foci of intraparenchymal haemorrhages in right posterior parietal lobe with mild midline shift of 2mm to left side.

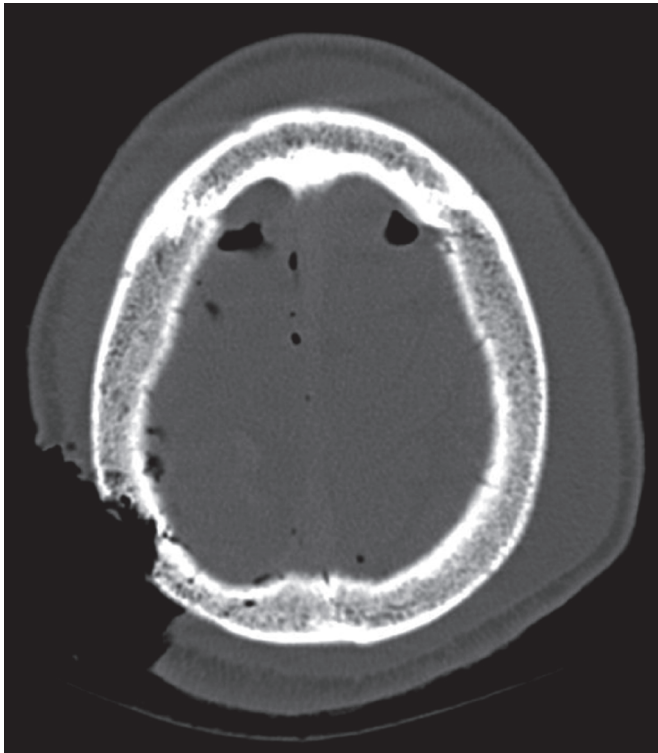


Figure 2. Full thickness bony erosions in right parietal region with pneumocephalus

After a week, the patient developed left sided hemiparesis, with no signs of meningitis. The repeat Computed Tomography of brain additionally showed resolving intraparenchymal haemorrhages with mass effect and midline shift of 4mm to left side (Fig.3).

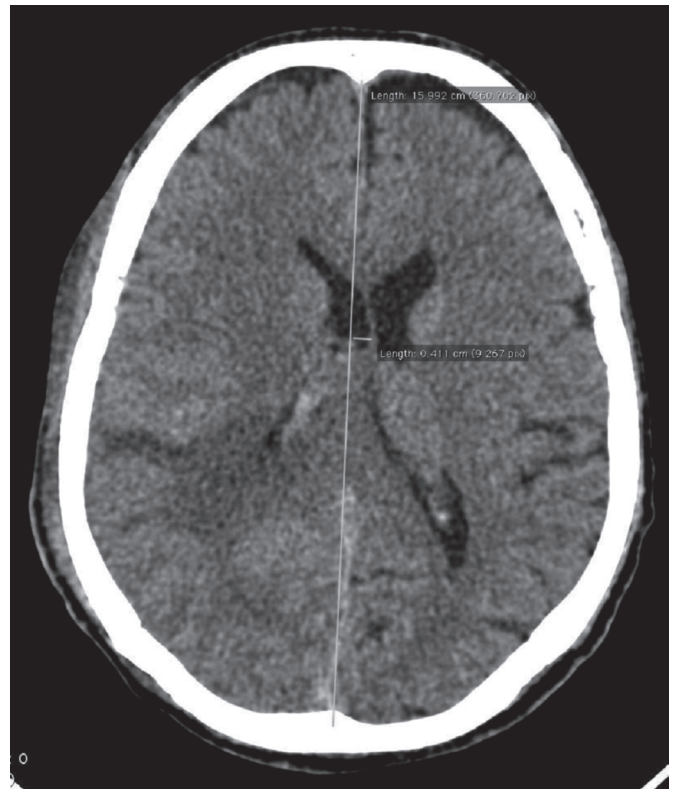


Figure 3. Intraparenchymal haemorrhages with midline shift of 4mm to the left side

The patient underwent multiple surgical debridements of the scalp wound and the herniating infected necrotic brain matter, resulting in a defect of 10*8cms, with placement of the G-Patch to cover the dural defect (Fig. 4).

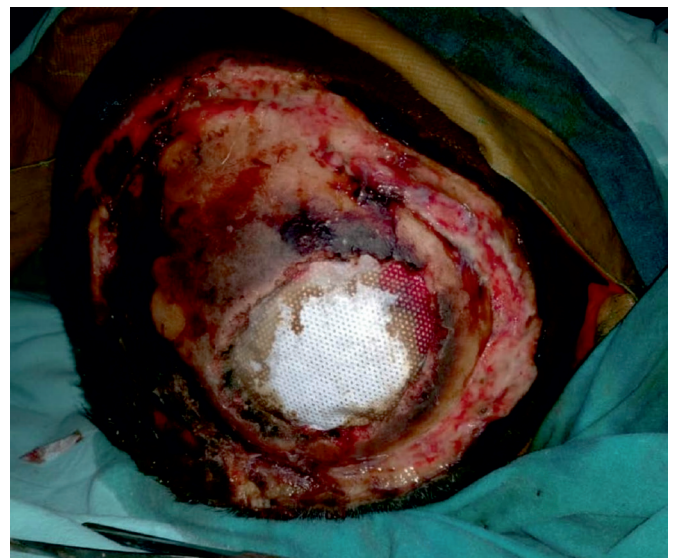

Figure 4. Placement of the G-Patch to cover the dural defect

The wound was serially dressed to prevent infection. The rest of the multiple limb burn wounds were debrided and split skin grafting was done thereafter.

A flap was raised to cover this defect, based on the posterior branch of the left superficial temporal artery. Since this flap could not cover the entire defect, multiple burr holes were made over the outer table of the skull, for allowing growth of granulation tissue. The donor areas were covered with skin grafts. (Fig. 5).

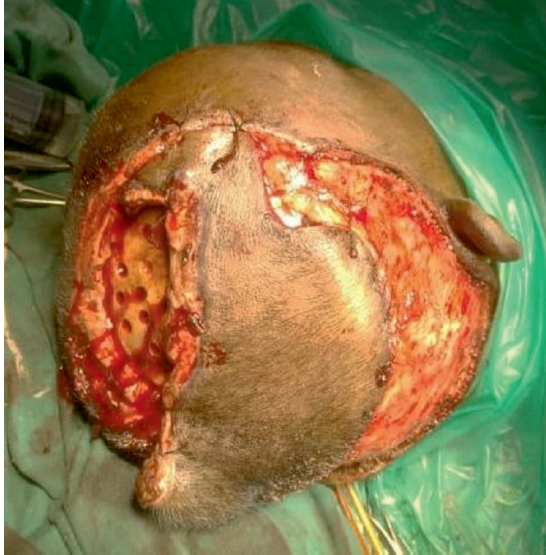


Figure 5. Flaps raised to cover the defect

After the success of the flap was confirmed, the remaining defect was covered by a forehead flap based on the anterior branch of left superficial temporal artery.

The flaps were viable and the postoperative period was uneventful. After daily dressings for 15 days, the scalp flap was kept open (Fig. 6). Patient was followed up for 2 months.

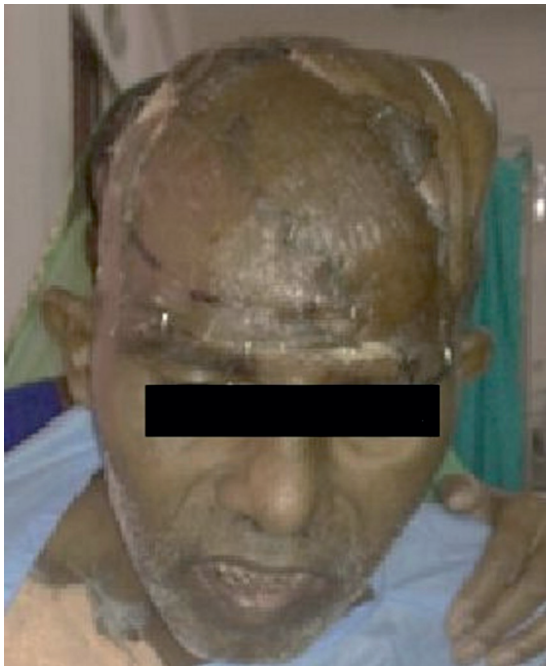

Figure 6. The flaps were viable when followed-up.

Discussion

Electric burn injuries are usually localized wounds with deep tissue destruction.^[3]

Injuries caused by electrical burns will appear superficial in nature to begin with but usually affect the deeper tissues as well. Successful outcome of treatment of such cases depends on:

1. understanding the anatomy of the injured
2. assessing the defect with an all-inclusive approach, and
3. selecting the most appropriate reconstructive procedure with the right planning of the various options.^[3]

In electric burn injuries, although electrical contact lasts only a fraction of a second or a few seconds, extremely high temperatures are generated. Electrical energy is converted to heat as current flows.^[4]

Thus the heat produced during the electric burns over scalp, can cause necrosis of one or both of the calvarial tables. The extent of the damage depends on the intensity of heat generation and the time duration. All these injuries require thorough surgical debridement of the devitalized tissues.^[3]

Muir has suggested that treatment of more extensive burns is often difficult and there is no general agreement as to the best method to adopt.^[5]

In present era many techniques are available to reconstruct the scalp defect in which local options like primary closure, skin grafting, local flaps are chosen first; then distant options like a free flap which includes fasciocutaneous or myocutaneous flap or muscle with graft, are chosen.^[6]

Some studies support the early debridement and early closure of scalp burn injury wounds to avoid infection. Whereas, a few authors prefer to delay it till the line of demarcation appears.

According to Victor et al, in electrical burns it takes about 7–10 days for a clear zone of demarcation to develop. As progressive tissue necrosis occurs, serial debridements are often required. Delayed reconstruction is advisable in these cases.^[7] The general condition of the patient including involvement of other systems should also be taken into consideration before planning a flap coverage procedure because the patient should be fit for a lengthy procedure, and if other areas which are burned need to be addressed earlier this may be delayed, provided the scalp wound is not infected.^[7]

In this case, we followed the multidisciplinary approach with the combined efforts of the neurosurgery and plastic surgery units. The patient underwent multiple serial debridements and a delayed two-staged flap coverage procedure.

Though there is a school of thought that supports early cover of scalp defects,^[8] in view of the progressive tissue necrosis in electrical burns it is better to plan free flap reconstruction at least 3 weeks after the injury.^[9] However more studies are required to come to a definite conclusion.

The ideal timing for tissue debridement has similarly been debated. According to another study conducted by Banerjee A et al, the ideal time to determine the presence of myonecrosis is typically 3 to 5 days following injury and once area of necrosis is delineated. Debridement of bone is performed until fine punctate bleeding points are visible.^[6]

The choice of ideal flaps for reconstruction depends upon the size and site of scalp defect.^[6]

Electric burns over scalp are extremely rare and their management varies on the basis of different factors and is also very controversial. Thus it can be concluded that the treatment options for each case of scalp electric burns differs according to the depth of involvement of the tissues, the surface area and location of the injuries and the response of the patient to the treatment depending on various patient factors. Full thickness scalp defect with exposed dura following electric burn injury can be covered with versatile scalp flaps with satisfactory functional and aesthetic results.

References

1. Paul K, Sharma S, Paul D. Bipedicle flap for reconstruction of post-electric scalp burn defect. *Int Surg J* 2017;4(5):1783-5.
2. Kaif M, Panwar DS, Ojha BK, Chandra A, Chandra N. High-voltage electrical burn of the head : Report of an unusual case. *IJNT* 2009;6(2):163-4.
3. Jeyakumar P, Hussain AT, Ahamed AR. Reconstruction of Extensive Post – Electric Burn Scalp Defects With Exposed Bones – A Study of 12 Cases. *Ann plast surg* 2018;0(0):1-6.
4. Hunt J, Purdue G, Spicer T. Management of Full-Thickness Burns of the Scalp and Skull. *Arch Surg* 1983;118:621-5.
5. Gajbhiye AS, Meshram MM. The Management of Electrical Burn. *Indian J Surg* 2013;75(Aug):278-83.
6. Banerjee A, Kumar N, Astha G. A Prospective Observational Study of Reconstruction of Post Electric Burn Scalp Defects. *IOSR-JDMS* 2016;15(5):85-90.
7. Victor J, Shetty N, Manickavachakan N, Dinakara D. An algorithmic approach to reconstruction of complex scalp defects in electric burns. *Indian J Burns* 2017;25:44-51.
8. Norkus T, Klebanovas J, Viksraitis S, Astrauskas T, Gelunas J, Rimkus R, et al. Deep electrical burns of the calvarium: Early or delayed reconstruction? *Burns* 1998;24:569-72.

9. Sarangal A, Gail P, Srivastava S. Delayed reconstruction with free flap: Answer to postelectric burn complex wounds: A 3-year experience. *Indian J Burns* 2015;23:32-6.

Conflict of interest: Nil

Source of funding: Nil

Date received: November 16th 2019

Date accepted: December 27th 2019